

## Tourette's Syndrome: A Pilot Study for the Discontinuance of a Movement Disorder

Anthony Sims, D.D.S.; Brendan Stack, D.D.S., M.S.

**ABSTRACT:** For a century and a half, Tourette's syndrome (TS) has been a mystery to the medical profession with physicians believing that it was a psychological disorder, then a neurological brain disorder, and then, an infectious disease caused by streptococcus. What was never considered was that this disorder called Tourette's was due to a structural deformity which would manifest itself as a neurological problem. What has been discovered is that Tourette's syndrome is neither psychological, infectious, genetic or environmental in origin, but is what we have termed a structural-reflex disorder, and have shown through this pilot study of multiple cases how and why Tourette's and its multiple co-morbid disorders can be discontinued with a device that requires no medicines or surgery called the Neurocranio Vertical Distractor (NCVD).

0886-9634/2701-011\$05.00/0. THE JOURNAL OF CRANIOMANDIBULAR PRACTICE, Copyright © 2009 by CHROMA, Inc.

Manuscript received October 25, 2007; revised manuscript received March 6, 2008; accepted August 12, 2008

Address for correspondence: Dr. Anthony Sims  
8865 Stanford Blvd.  
Suite #131  
Columbia, MD 21045  
E-mail: absimsdds@hotmail.com

*Dr. Anthony B. Sims received his D.D.S. degree from The Ohio State University in 1983. Currently, he has a general dental practice in Columbia, Maryland, where he also treats TMD and snoring/sleep apnea patients. His research interest is in understanding how dentistry interrelates with the many different types of movement disorders. To view the discontinuance of movement disorders associated with Tourette's syndrome and other disorders go to <http://www.absimsdds.com> and click TMD/Movement disorder/video.*

Tourette's syndrome (TS) is defined as an inherited neurological disorder that is a chronic idiopathic syndrome characterized by the presence of multiple motor tics and vocal tics that have their beginning before adulthood (usually with an onset in childhood between ages 5-8).<sup>1-3</sup> Tics are repetitive, stereotypic movements or phonetic events, that are nonrhythmic and involuntary (motor tics) such as blinking, coughing, sniffing, shoulder shrugging, neck stretching and throat clearing. Tourette's syndrome is one of several disorders which are classified by the diagnostic and statistical manual of mental disorders (DSM) according to type (motor or vocal) and duration (transient or chronic) from the American Psychiatric Association, 2000.

### Diagnosis criteria for Tourette Syndrome (TS) (DSM-IV-TR 307.23)

1. The onset is before 18 years old;
2. The tic is not due to the direct effect of substance (e.g. Stimulants) or medical condition (e.g., Huntington's Disease or Postural Encephalitis);
3. Tics occur multiple times a day for more than one year and there was not a tic free period for more than three consecutive months;
4. Both multiple motor and vocal tics are present and are not concurrent.

Tourette's syndrome was originally thought to be a rare and severely bizarre disorder, most often associated



with coprolalia, which occurs in approximately 10% of those with Tourette's, as where now TS is understood to be less rare and often classified as a mild condition but having a wide range of severity.<sup>4</sup>

Patients with Tourette's seem to have normal intelligence and a normal life expectancy. The most common disability is within a social setting and those with TS find it embarrassing when severe movements or vocalizations occur.<sup>5</sup> People with Tourette's can achieve success in all walks of life, from athletics to professional careers. However, prejudice or ostracizing is very common at school or at work.<sup>6,8</sup>

The severity of tics usually decreases as patients grow into adolescence. It is estimated that approximately 0.5%-2% of school-age children have some type of tic. Transient tics can occur in up to 3-15% in children. Tics can also interrupt an individual's behavior and thoughts. Most patients find that they sometimes lose track of conversation or that they are slow to complete a task because of incessant interruption by their tics.<sup>7</sup> Tourette's tics can sometimes be temporarily suppressible and/or preceded by a premonitory urge, which is similar to the need to sneeze or scratch an itch.<sup>9</sup> Many patients describe the sensation as a build-up of tension or a need to release as something they had to do. The tic is released or relieved. This is known as the *premonitory sensory phenomena*.

When a person with Tourette's suppresses their tics, the tics will subsequently result in an explosion of tics, and the person may seek a secluded spot to release their symptoms.

There is no such thing as a typical TS case. A number of non-tic symptoms can occur concomitantly with TS. Some patients exhibit symptoms of attention deficit hyperactive disorder (ADHD),<sup>10</sup> and/or obsessive compulsive disorder (OCD),<sup>11</sup> anxiety and depression. As with most movement disorders, tics are worse at times of stress and are decreased during sleep.<sup>12,13</sup> Tics tend to improve when a person is engaged in an activity that is challenging.

#### *History and Diagnosis of Tourette's Syndrome*

In 1885, Dr. Gilles de la Tourette's published the "*Study of a Nervous Affliction*" which described nine patients with this disorder. Many ideas have been postulated since this time as to the origin of this disorder, including brain lesions, inconsistent brain circuit mechanism, encephalitis and psychoanalytic theories. The psychogenic view was so dominant at the time that the claim for any causal organic condition could not be sustained by itself as a cause of Tourette's syndrome. Psychiatric treatment became the preferred method, because physicians believed that the disorder was caused by some psy-

chological disturbance of psychosexual conflict. This was the medical method of treatment until the early 1970s. Motor tics have been postulated since the 1990s to be the result of a dysfunction of the cortical and subcortical regions, the thalamus, basal ganglia, and the frontal cortex. Neuroanatomic models implicate failures in the circuits connecting the brain's cortex and subcortex and imaging techniques implicate the basal ganglia and frontal cortex.<sup>14-16</sup>

TS is based on symptoms observed as described in the DSM and family history and ruling out secondary causes of the disorders. A PET scan, a CAT scan, and an MRI may be required to rule out brain abnormalities. Usually treatment is focused on relief of symptoms.<sup>17-19</sup> Various medicines have been prescribed for treatment of TS. Such medicines are neuroleptics, i.e., haloperidol which has the only Food and Drug Administration (FDA) approval for the treatment of this disorder. Risperidone is used for tics. There are many side effects associated with these medicines. The antipsychotic medicines may cause fatigue, nausea, dystonia, Parkinsonism, deregulation of body temperature, increase in serum prolactin (hyperprolactinemia), and/or headaches. The benzodiazepines may cause or exacerbate preexisting states of confusion and hallucination or tardive dyskinesias. Also sedation, ataxia, and cognitive difficulties are associated with some of these medicines. The physician finds himself prescribing secondary medications to ameliorate the side effects of the initial medication.

One of the new treatments for TS movement disorders is the injection of the neurotoxin produced by the bacteria *Clostridium botulinum*, where the neurotransmitters that cause muscles to contract are inhibited. This treatment is repeated every three to four months. Patients may develop antibodies to the toxin rendering the treatment ineffective. Temporary weakness in the muscles that are being injected is usually one of the side effects that occur. Also flu-like symptoms may be evident.<sup>20,21</sup>

When there is a severe movement disorder and the medicines mentioned don't work or have become ineffective, surgery may be recommended. There are two differing types of surgery. One is called Deep Brain Stimulation (DBS) and the other is Ablative surgery. In DBS, a neurotransmitter is implanted to deliver an electrical stimulation to the area of the brain that controls bodily movement. The electrical impulse blocks the nerve signals that trigger abnormal movements. A small incision is made into the skull and an electrode is placed inside the brain extending to the area of abnormality within the brain. An insulated wire is passed through the skin of the neck, shoulder, and chest to the neurostimulator placed in the upper abdomen. These surgeries are about 75% effective



in their treatment of movement disorders and may include multiple side effects. However, these surgeries have recently been questioned and have not been promoted for the treatment of TS.<sup>22</sup>

TS patients will sometimes exhibit comorbid conditions that may occur with their symptoms. Some patients have shown the following associated conditions:

- A. Attention Deficit Hyperactive Disorder (ADHD).
- B. Obsessive Compulsive Disorder (OCD)
- C. Sleep Disorder
- D. Increased Enuresis in children
- E. Bipolar Disorder

Not all TS patients will have these associated conditions and it is not a certainty or requirement that these conditions exist with this disorder. The majority of TS patients have only the movement disorder with the absence of associated disorders.

#### *Causes and Origin of Tourette's Syndrome and Tics*

For 150 years, the neurological structure for TS was not understood. We have known for sometime the anatomy of the stomatognathic system. Yet the connection between TS and the stomatognathic system has never been made until now.

Tourette's syndrome has been promoted as having no known origin. It has been suggested that it has an inherited genetic link,<sup>23,24</sup> or there are environmental factors, or there may be an autoimmune process which causes the tics or Tourette's; or symptom onset and/or exacerbation is precipitated by streptococcus infection (Pediatric autoimmune neurological disorder associated with streptococcus known as PANDAS).<sup>25-27</sup> This hypothesis describes TS as of prepubescent, sudden, explosive onset and/or exacerbation and remissions and that is temporary. In the April 2004 issue of Pediatrics, researchers Kurlan and Kaplan reviewed current scientific information and concluded "that PANDAS remains a yet unproven hypothesis." It has also been suggested that the mechanism for tics results from a dysfunction in the cortical and subcortical regions, the thalamus, basal ganglia or the frontal cortex.

The largest cranial nerve, the trigeminal, CN V, has three divisions: ophthalmic, maxillary, and mandibular. It is predominantly a sensory afferent nerve with the mandibular division having somatic efferent motor fibers. There is a collection of neurons in the brainstem called the trigeminal nucleus and the bodies of these neurons run within the midbrain, the pons, and the medulla. Most trigeminal sensory fibers enter the trigeminal ganglion regardless of which of the three divisions it originates. Large diameter afferent "A" sensory *fast pain* fibers enter the trigeminal ganglion and incoming somato-afferent

neurons synapse and cross within the pons. Secondary afferent neurons continue up the posterior trigeminothalamic tract to the thalamus. The small diameter "C" sensory fibers associated with pain and temperature enter at the middle of the pons and turn inferiorly in the brainstem along the spinal tract of V terminating in the spinal cord at the level of C-1 and C-2. The lower portion of the spinal tract of V is called the subnucleus caudalis, and this is where the afferent "C" fibers synapse, cross and turn superiorly through the anterior trigeminothalamic tract to the thalamus. Interestingly, cranial nerves VII, IX, and X also transmit fibers through the subnucleus caudalis (Figure 1). There are mechanoreceptors and proprioceptive input (A-beta and A-alpha) fibers located within the spinal tract of V. Nociceptive pain is caused by the stimulation of peripheral nerves with A-delta and C-polymodal pain receptors. Electrical connections can occur between adjacent demyelinated axons. These are referred to as ephapses.<sup>28-30</sup> *Ephaptic cross talk* may result in the transfer of nerve impulses from one axon to another. Cross talk between A and C fibers develops in the dorsal root ganglion. In the brain stem, the main nociceptive relay station is the superficial layer of the trigeminal subnucleus caudalis (substantia gelatinosa) which receives primary afferent inputs of myelinated A and unmyelinated C fibers from the orofacial region.

The maxillary and mandibular divisions are entirely sensory with the mandibular division having a small amount of efferent motor fibers. The pathways of CN V are such that impulses travel from receptors, via the A alpha and C nerve fibers to the Gasserian peripheral proprioceptive ganglion and then to the spinal cord level of C-1 or C-2. The spinal tract of V turns caudally at the level of C-1 or C-2. It is at this level where the neurons of the subnucleus caudalis cross over within the spinal cord from which second order neurons within the spinal cord (substantia gelatinosa) travel superiorly upward toward the thalamus and on to the cerebral cortex (Figure 2).

Many movement disorders are believed to be disjunctions within the thalamus-cortex-substantia nigra connections. However, the authors believe the neuroanatomy of this movement disorder does not rise to the high level of these connections, but is a reflexive disorder that occurs at the spinal cord level within the spinal trigeminal nucleus, specifically the subnucleus caudalis. CN V sensory information is processed and modified at each level in the chain by interneurons and by input from other areas of the nervous system.

Frequently one of the first clinical signs of TS is repetitive and uncontrollable eye blinking. If the pathway for the blink reflex is examined, we notice that CN V trans-



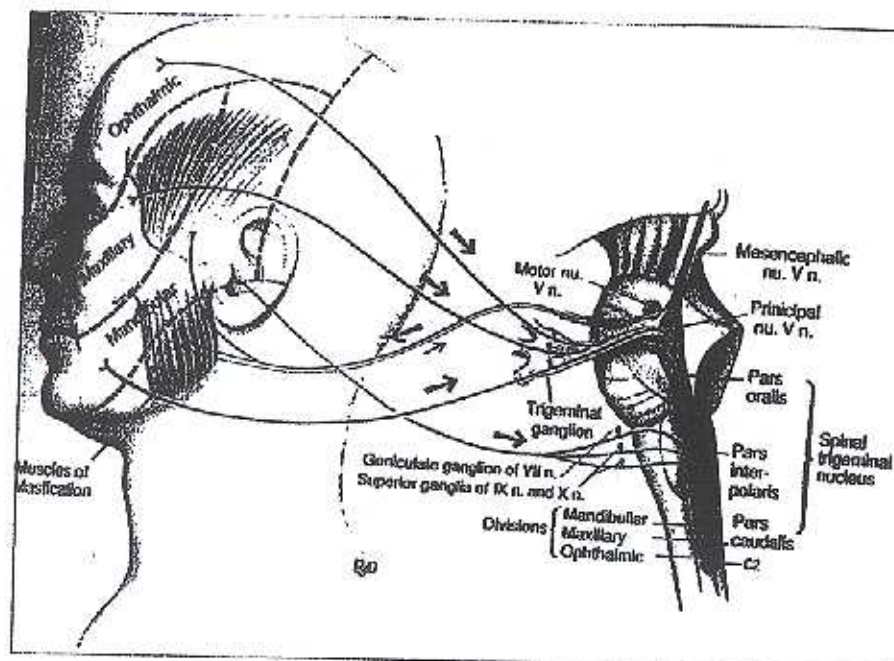


Figure 1

The muscle and innervation of the TMJ region. Cranial nerves VII, IX, and X transmit fibers through the subnucleus caudalis. Figure used with permission from *The Human Nervous System* by Charles Noback and Robert Demarest, 2005 ed; Totowa, New Jersey: Humana Press.

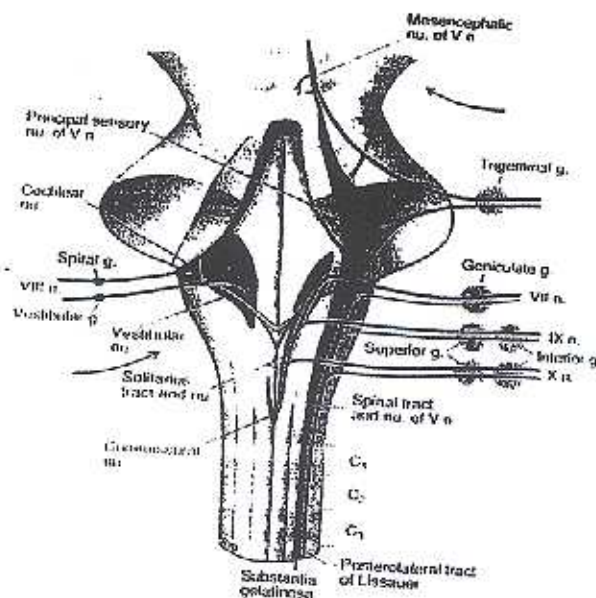


Figure 2

The neurons of the subnucleus caudalis cross over within the spinal cord from which second order neurons within the spinal cord (substantia gelatinosa) travel superiorly upward toward the thalamus and on to the cerebral cortex. Figure used with permission from *The Human Nervous System* by Charles Noback and Robert Demarest, 2005 ed; Totowa, New Jersey: Humana Press.

mits tactile sensation from the cornea, which is perceived as irritation that evokes bilateral eyelid closure (an eye blink). Trigeminal ophthalmic primary afferents send signals which end in the spinal trigeminal nucleus (subnucleus caudalis). From here, interneurons connect to the reticular formation. Within the reticular formation, interneurons send signals to the facial nucleus, cranial nerve VII. Facial nerve efferent neurons from the facial nucleus send their signal to the orbicularis oculi which closes the eyelid; blinking occurs. This is the simplified version of the corneal blink reflex neural circuit.<sup>31</sup>

We believe the primary incoming afferent signals can come from other sensory branches of the trigeminal nerve itself. This is what may cause the reflex arc to occur. Very frequently and often unobserved low order but constant nociceptive impulses transmitted by the auriculotemporal nerve, with its vast number of sympathetic fibers, come into the trigeminal ganglion and using the above described afferent neural pathway, and end in the subnucleus caudalis through ephaptic transmissions.<sup>32-34</sup>

Motor efferent nerves from this nucleus may stimulate other muscles of facial expression such as frontalis, orbicularis oris, platysma, and zygomaticus major and minor, etc. These are some of the muscle groups which are implicated in facial motor tics. We believe that it is the afferent sensory fibers in the mandibular division of CN V that are causing oromandibular dyskinesia to be manifested into and through CN VII.

Another frequent finding in TS is throat clearing and sniffing. Examining the anatomy of the trigeminal nerve, one can see that within the spinal tract of V, which



ends in the subnucleus caudalis, there are connections within the subnucleus caudalis to the glossopharyngeal nerve, CN IX, which contains general sensory fibers and provides sensation from the posterior 1/3 of the tongue, tonsil, skin of the external ear, internal surface of the tympanic membrane, and the pharynx (Figure 3). When this nerve is chronically stimulated, the cough/gag reflex becomes paramount. If the primary chronic stimulus was not from CN IX, but was from chronic ephaptic stimulation within the subnucleus caudalis where CN IX and CN V decussate, would not the cough/gag reflex be stimulated?

A well-documented finding in many movement disorder patients with TS is echolalia (the spontaneous utterance of sounds). Examining the anatomy within the subnucleus caudalis, one can see that the vagus nerve, CN X decussates within the spinal trigeminal nucleus as does CN V.

CN X is a general sensory afferent nerve providing sensation from the posterior meninges, concha, and skin at the back of the ear and in the external acoustic meatus, part of the external surface of the tympanic membrane, the pharynx and the larynx (the vocal cords). As a result of its irritation, the voice feels hoarse and a clearing of the throat results. We believe that if the primary irritant was not from CN X itself but originated from CN V within the subnucleus caudalis' ephaptic connections, the vocal expressions of echolalia (throat clearing, grunting, or barking sounds) would occur.

Another documented clinical sign with those who have TS is shoulder shrugging. We know that the muscles of the neck (sternomastoid) and shoulder (trapezius) are innervated by the spinal accessory nerve, CNXI. This nerve originates at the level of C1 through C5 as rootlets from the anteriolateral portion of the anterior horn of the spinal cord. The myelinated fibers of the spinal tract of V and the large spinal nucleus of V also extend to the level of C2. The ventral horn of cranial nerve XI gives rise to the motor portion of the nerve, and it also goes to the level of C2.<sup>35</sup> Second and most importantly, the trigeminal nerve also projects primary afferent nerves to the reticular formations raphe nuclei which stimulate the medial and lateral nucleus portions of the reticular formation. These areas project both rostrally and caudally throughout the brainstem's tegmentum and influences both the autonomic and voluntary muscle reflexes. According to the textbooks by Alf Brodal, *The Central Nervous System* (2004), and Charles Noback, *The Human Nervous System* (2005), the pontine medial reticular formation, when stimulated, mediates posture and orients head and neck movements and turns them to the ipsilateral side. These reticular cell groups are called premotor

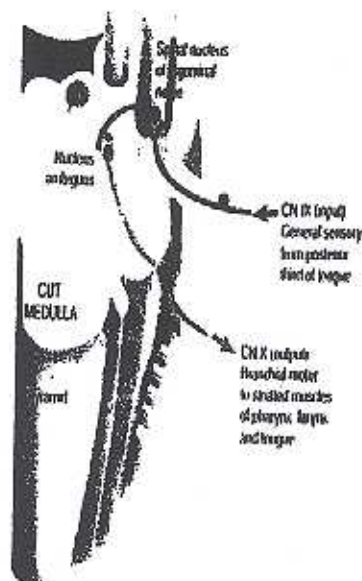


Figure 3

Examining the anatomy of the trigeminal, we see that within the spinal tract of V, which ends in the subnucleus caudalis, there are connections within the subnucleus caudalis to the glossopharyngeal nerve, CN IX, which contains general sensory fibers and provides sensation from the posterior 1/3 of the tongue, the tonsil, the skin of the external ear, the internal surface of the tympanic membrane and the pharynx. Figure used with permission from *Cranial Nerves in Health and Disease*, 2nd ed. Wilson-Pauwels L, Lewiston, New York: B.C. Decker, Inc.

networks and they control activity of large groups of muscles such as in the neck, trapezius, sternocleidomastoid and axial muscles. This is the area when stimulated by CN V, implicates the shoulder shrugging and head turning.

### The Neurological Aspects of Dentistry

What would cause constant noxious irritation of CN V, particularly the auriculotemporal nerve? Correct growth of the face, head, and neck require that four factors must occur simultaneously. The (1) base of the cranium must grow properly, (2) the maxillo-naso complex must develop downward and forward in conjunction with the cranium, (3) the maxilla must grow to its fullest potential vertically, sagittally, and transversely, and (4) the airway must develop unobstructed. If there is a mal-relationship between any of these areas of development, complications from the temporomandibular joint may result as an attempt to compensate for developmental discrepancies.

In the book, *Facial Growth and Facial Orthopedics*,



by Frans Van der Linden (1986), it is stated that 90% of cranial growth is completed by age five, the development of the maxilla by age seven, and the mandible by age nine. In TS patients, the symptoms begin to manifest themselves between the ages five to nine years, the years of greatest change.

In a simplified version, the direction of facial growth is downward and forward. Every area of the mandible participates directly with its remodeling. Some areas of the mandible grow faster and are more active than others. The corpus of the mandible grows down and forward, while the direction of the ramus growth is postero-superior. When condylar growth is directed upwards and backwards toward the glenoid fossa of the cranial base, while simultaneously cranial growth is downward and forward, the result is that the maxilla and mandible are repositioned downward and forward. The final result is dependant on how the different craniofacial structures interrelate. When the maxilla and mandible do not achieve their genetic potential in length, width, or vertical position, the effects are seen in mal-relationships and dysfunctions in the patient's tissues, bones, muscles, and nerves. The temporomandibular joint (TMJ) relationship may then become compromised when this occurs, as it compensates for the discrepancies in normal growth and development.

Normal spacing between the roof of the glenoid fossa of the temporal bone and the condyle of the mandible should be approximately three mm to support the disk between them. The retrodiskal tissues originate from the distal portion of the glenoid fossa and are inserted into the posterior portion of the disk. This tissue contains a matrix of blood vessels and nerves, particularly fibers of the auriculotemporal nerve, cranial nerve V, an afferent branch of the trigeminal nerve. If this space is insufficient or reduced or restricted and the condylar head grows posterosuperiorly or is iatrogenically repositioned posteriorly or posterosuperiorly, the condyle will pinch this tissue and usually the result will be pain. In TS, the result is the same impingement of the retrodiskal tissues to a lesser degree, and enough stimuli does not exist for the impingement to be painful. What occurs is a constant neuritis, a stimulation of the "C" nerve fibers of the auriculotemporal nerve sufficient to cause a lower level of chronic irritation (itchiness or a premonitory urge). This triggers a constant low level input via the auriculotemporal nerve to the Gasserian ganglion and then to the spinal nucleus and subnucleus caudalis of CN V.

Constant stimulation of the auriculotemporal nerve (CN V) may then result in the stimulation of CN's V, VII, IX, X, via crossover interneurons (ephapses) and other neural elements in the reticular formation. All of these

nerves are intimately involved with movement disorders. In summary, we find that chronic noxious input via the auriculotemporal nerve causes reflex reactions with CN's V, VII, IX, and X via the crossover pathways at various segmental levels within the spinal cord.

This is the reason, eliminating chronic noxious input into the central nervous system, the procedure utilizing the Neurocranio Vertical Distractor relieves movement disorders associated with TS. With the procedure, we artificially remove the neuritis (constant stimulation and irritation of the auriculotemporal nerve) by placing the mandible into its proper anatomical position, downward and forward in relation to the patient's cranial base. Consequently, there is no constant conduction of noxious impulses into the subnucleus caudalis and therefore no constant irritation of CN's V, VII, IX, and X including the reticular formation which are some of the nerves implicated in the movement disorder.

### Methods and Materials

Six patients with movement disorders are presented: ages seven, 25, 36, 36, 40 and 52. Five patients were given a diagnosis of tic disorder and/or Tourette's syndrome by their neurologist, and one had a full body tremor movement after having a maxillary molar extracted. The Yale Global Tic Severity Scale was the protocol used to judge each patient's symptoms (Table 1) with the exception of the patient that had the molar extraction. Each patient was then given a comprehensive temporomandibular joint examination and a history taken. In all cases there where no medicines given, no medicines were being taken for any length of time, minimum of one month, and all patients except one were videotaped and that one patient gave a statement to their condition and results. Follow up was at three, six, and 12 month intervals.

Five patients were given a test to determine the approximate intermaxillary vertical dimension and posture of the mandible. The basic test is to vertically reposition the teeth and lower jaw, artificially placing the mandible into a position that causes a diminution of the movement disorder. Vertically adjustable spacers, approximately two mm each in height were used to raise and flexibly manipulate the position of the mandible and therefore relieve the effects associated with improper TMJ spacing. When the proper position of the mandible was determined and stabilized, the movement disorders immediately ceased.

Impressions of the mandible were then taken and were sent to a lab for the fabrication of a Neurocranio Vertical Distractor (SS NCVD) appliance (Figures 4 and 5). This appliance holds the lower jaw in the position that had



**Table 1**  
**The Yale Global Tic Severity Scale**

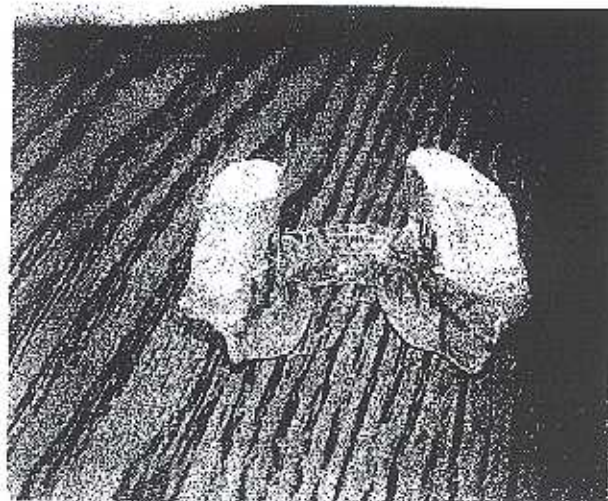
	PT 1	PT 2	PT 3	PT 4	PT 5	PT 6
Eye movement	X	X	X	X	X	NA
Facial grimacing	X	X	X	X	X	NA
Head jerk movement	X		X		X	NA
Shoulder jerk movement	X		X	X	X	NA
Arm or hand movement	X		X			NA
Leg, foot movement			X			NA
Abdominal/trunk, pelvis movement	X	X	X			NA
Bending, gyrating complex motor tics	X		X			NA
Phonic tic	X		X			NA

been determined. Upon return of the appliance, the vertically adjustable platforms of the NCVD were either increased or lowered with respect to the discontinuance of the movement disorder. Then clear orthodontic acrylic was added to the platform and cured to stabilize the tooth position and also to determine the final maxillary and mandibular position. All patients showed a total discontinuance of their movement disorders immediately. All patients stated that their breathing was improved and better. All patients stated they did not have the urge to tic or make their involuntary movements. An upper appliance was made for the seven-year-old patient and again, the movement disorder ceased.


#### **Conclusion: Health Concerns**

This procedure eliminates the chronic noxious stimuli into the CNS via the auriculotemporal nerve, by decreasing and/or eliminating the movement disorder involving tics and the associated co-morbid conditions. With this procedure, we remove the neuritis (constant stimulation and irritation of the auriculotemporal nerve which produces the premonitory urge and place the mandible into its proper anatomical position downward and forward in relation to the patient's cranial base). Therefore, there will not be a constant impulse into the subnucleus caudalis and therefore no constant irritation of CN V, VII, IX, and X with the associated RF neurons which are the nerves implicated in the movement disorder.

With this procedure, one can redirect a child's growth pattern early enough so as to prevent these movement disorders from ever occurring and guide them into a normal growth pattern. This will decrease the patient's need for additional health services. It will increase their chances of having increased acceptance socially among their peer



**Figure 4**  
Neurocranio Vertical Distractor (patent pending).



**Figure 5**  
Neurocranio Vertical Distractor (different view) (patent pending).



groups without being construed as having emotional disturbances or learning disabilities. It will increase their overall general health, because with the waxing and waning of those with movement disorders, physicians cannot truly evaluate the patients without getting a distorted evaluation.

Other questions now arise as to the study of radiological evaluations of those with TS and other movement disorders. Are we looking in the right places? It brings into question "are other movement disorders from the spinal cord and brainstem or are they from the brain itself?" This procedure shows how integral the maxillo-mandibular relationship is to the entire body and that all of those involved in the medical profession are interested in all aspects of the human body and how interrelated each part of the body is. Our medical community should encourage each specialty to be involved with solving all the diseases of the body no matter how aberrant they may seem. Results obtained from this pilot study suggest that through the use of the Neurocranio Vertical Distractor and the significant discontinuance of the movement disorder associated with Tourette's syndrome, there is a correlation between the position and growth of the mandible, the temporomandibular joint, and the neurological connections of cranial nerve V. A more long-term study is needed to enhance these results.

## References

- Jankovic J: Tourette's syndrome. *N Engl J Med* 2001; 345(16):1184-1192.
- Keen-Kim D, Pricer MB: Genetics and epidemiology of Tourette syndrome. *J Child Neurol* 2006; 21(8):665-671.
- Marcus D, Kurlan R: Tics and its disorders. *Neurol Clin* 2001; 19(3):735-758, viii.
- Pauls DL, Leckman JF: The inheritance of Gilles de la Tourette's syndrome and associated behaviors: evidence for autosomal dominant transmission. *N Engl J Med* 1986; 315(16):993-997.
- Coffey BJ, Miguel EC, Savage CR, Rauch SL: Tourette's disorder and related problems: a review and update. *Harv Rev Psychiatry* 1994; 2(3):121-132.
- Kurlan R, et al.: Prevalence of tics in schoolchildren and association with placement in special education. *Neurol* 2001; 57(8):1383-1388.
- Burd L, Freeman RD, Klug MG, Kereshian J: Tourette Syndrome and learning disabilities. *BMC Pediatr* 2005; 5(1):34.
- Singer HS, Schuerholz LJ, Denckla MB: Learning difficulties in children with Tourette syndrome. *J Child Neurol* 1995; 10(Suppl):S58-61.
- Kwak C, Dai Vuong K, Jankovic J: Premunitory sensory phenomenon in Tourette's syndrome. *Mov Disord* 2003; 18(12):1530-1533.
- Hiederman J, Newcorn J, Sprich S: Comorbidity of attention deficit hyperactivity disorder with conduct, depressive, anxiety, and other disorders. *Am J Psych* 1991; 148(5):564-577.
- Carter AS, Pollock RA, Suvak MK, Pauls DL: Anxiety and major depression comorbidity in a family study of obsessive-compulsive disorder. *Depress Anxiety* 2004; 20(4):165-174.
- Allen RP, Singer HS, Brown JE, Salam MM: Sleep disorders in Tourette syndrome: a primary or unrelated problem? *Pediatr Neurol* 1992; 8(4):275-280.
- Kostanecka-Endress T, et al.: Disturbed sleep in children with Tourette syndrome: a polysomnographic study. *J Psychosom Res* 2003; 55(1):23-29.
- Garraux G, Goldfine A, Bohlhalter S, Lerner A, Harukawa T, Hallett M: Increased midbrain gray matter in Tourette's syndrome. *Ann Neurol* 2006; 59(2):381-385.
- Harris K, Singer HS: Tic disorders: neural circuits, neurochemistry, and neuroimmunology. *J Child Neurol* 2006; 21(8):678-69.
- Stern E, et al.: A functional neuroanatomy of tics in Tourette syndrome. *Arch Gen Psych* 2000; 57(8):741-748.
- Kurlan R: Tourette syndrome. Treatment of tics. *Neurol Clin* 1997; 15(2):403-409.
- Robertson MM, Stern JS: Gilles de la Tourette syndrome: symptomatic treatment based on evidence. *Eur Child Adolesc Psych* 2000; 9(Suppl):160-175.
- Singer HS, Walkup JT: Tourette syndrome and other tic disorders. Diagnosis, pathophysiology, and treatment. *Medicine* 1991;70(1):15-32.
- Bosca-Busca ME, Burguera-Hernandez JA, Roig-Morata S, Martinez-Torres I: Painful tic convulsive and botulinum toxin. *Rev Neurol* 2006; 42(12):729-732.
- Jankovic J: Botulinum toxin in movement disorders. *Curr Opin Neurol* 1994; 7(4):358-366.
- Diamond A, Jankovic J: The effect of deep brain stimulation on quality of life in movement disorders. *J Neurol Neurosurg Psych* 2005; 76(9):1188-1193.
- Abelson JF, et al.: Sequence variants in SLITRK1 are associated with Tourette's syndrome. *Science* 2005; 310(5746):317-320.
- Deng H, Le WD, Xie WJ, Jankovic J: Examination of the SLITRK1 gene in Caucasian patients with Tourette syndrome. *Acta Neurol Scand* 2006; 114(6):400-402.
- Church AJ, Dale RC, Lees AJ, Giovannoni G, Robertson MM: Tourette's syndrome: a cross sectional study to examine the PANDAS hypothesis. *J Neurol Neurosurg Psych* 2003; 74(5):602-607.
- Kurlan R: Tourette's syndrome and 'PANDAS': will the relation bear out? Pediatric autoimmune neuropsychiatric disorders associated with streptococcal infection. *Neurol* 1998; 50(6):1530-1534.
- Singer HS, Hong JJ, Yoon DY, Williams PN: Serum autoantibodies do not differentiate PANDAS and Tourette syndrome from controls. *Neurol* 2005; 65(11):1701-1707.
- Montero J, Junyent J, Calopa M, Povedano M, Valls-Sole J: Electrophysiological study of ephaptic axon-axon responses in hemifacial spasm. *Muscle Nerve* 2007; 35(2):184-188.
- Voronin LL: Intrasympathic ephaptic feedback in central synapses. *Neurosci Behav Physiol* 2000; 30(5):575-585.
- Voronin LL, Volgushev M, Sokolov M, Kasyanov A, Chistiakova M, Reymann KG: Evidence for an ephaptic feedback in cortical synapses: postsynaptic hyperpolarization alters the number of response failures and quantal content. *Neuroscience* 1999;92(2):399-405.
- Tamai Y, Iwamoto M, Tsujimoto T: Pathway of the blink reflex in the brainstem of the cat: interneurons between the trigeminal nuclei and the facial nucleus. *Brain Res* 1986; 380(1):19-25.
- Di Lazzaro V, et al.: Preliminary clinical observations on a new trigeminal reflex: the trigemino-cervical reflex. *Neurology* 1996; 46(2):479-485.
- Dostrovsky JO, Hu JW, Sessle BJ, Sumino R: Stimulation sites in postganglionic gray, nucleus raphe magnus and adjacent regions effective in suppressing oral-facial reflexes. *Brain Res* 1982; 252(2):287-297.
- Bokun S, O'Shaughnessy CT, Gough PJ: Properties of neurons in the trigeminal nucleus caudalis responding to noxious dental and facial stimulation. *Brain Res* 2005; 1046(1-2):122-129.
- Frumkin SC, Kyle MA: The dentist's contribution to rehabilitation of cervical posture and function: orthopedic and neurological considerations in the treatment of craniomandibular disorders. *Basal Facts* 1987; 9(3): 105-109.

**Dr. Brendan C. Stack** is a university-trained orthodontist who has limited his practice to orthodontics, craniofacial pain, and TMJ disorders for the past 42 years. Having graduated from Georgetown University, he is also the Tufts' University (Boston) 2003 recipient of their "Lifetime Achievement Award" for his years of contribution to the field of craniofacial pain. In the United States and Europe, he is frequently an invited lecturer on the topics of TMJ and craniofacial pain. He has published peer reviewed literature on the long-term results of his treatment procedures. Having contributed chapters to TMJ textbooks and written numerous articles and manuals on the diagnosis and treatment planning of craniofacial pain patients, he has also produced videotapes of his treatment technique to teach other doctors. Dr. Stack shows that the frequent symptoms of these patients are due to dysfunctions of the stomatognathic system, and how to recognize and correct these abnormalities. He is a founding member and was the first president of the American Academy of Craniofacial Pain and is a diplomate of the American Board of Craniofacial Pain. He is a member of the International Headache Society, the American Pain Society, and the American Association of Orthodontics.